Chapitre 5
Système digestif

Système digestif: finalité et utilité

- Finalité du système digestif
- Gérer l'économie: Hydrates carbone, Acides aminés, Acides gras
- Gérer apport d'H_2O, Vitamines, Minéraux
- Contrôle et régulation du pH sanguin (H^+, HCO_3^-)
- Eliminer déchets métabolisme, métabolites hormones, toxines, médicaments

Système digestif: structure générale

- Gestion matière haute énergie biochimique: Transformation énergétique
  - *Rein: échange matière* *Digestif: transformation matière*
- Transport de matière, d'énergie et d'information
- Géométrie de construction: tuyauterie complexe segmentée/compartimentée
- Architecture tubaire et vasculaire (foie)
- Organisation spatiale
  - Organes creux: tube digestif
  - Organes pleins: système glandulaire/hormonal
- Régulation et limites: Boucle fermée ; Plateau (non-linéarité)

Système digestif: principes généraux

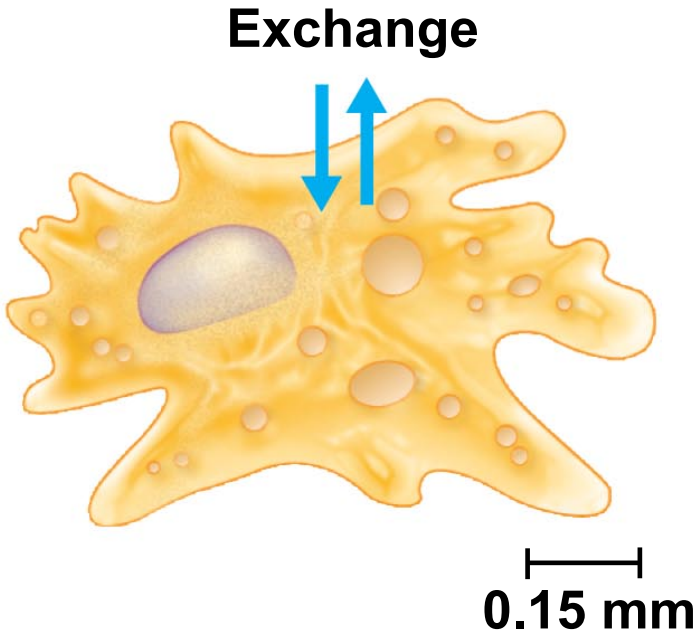

(a) Single cell

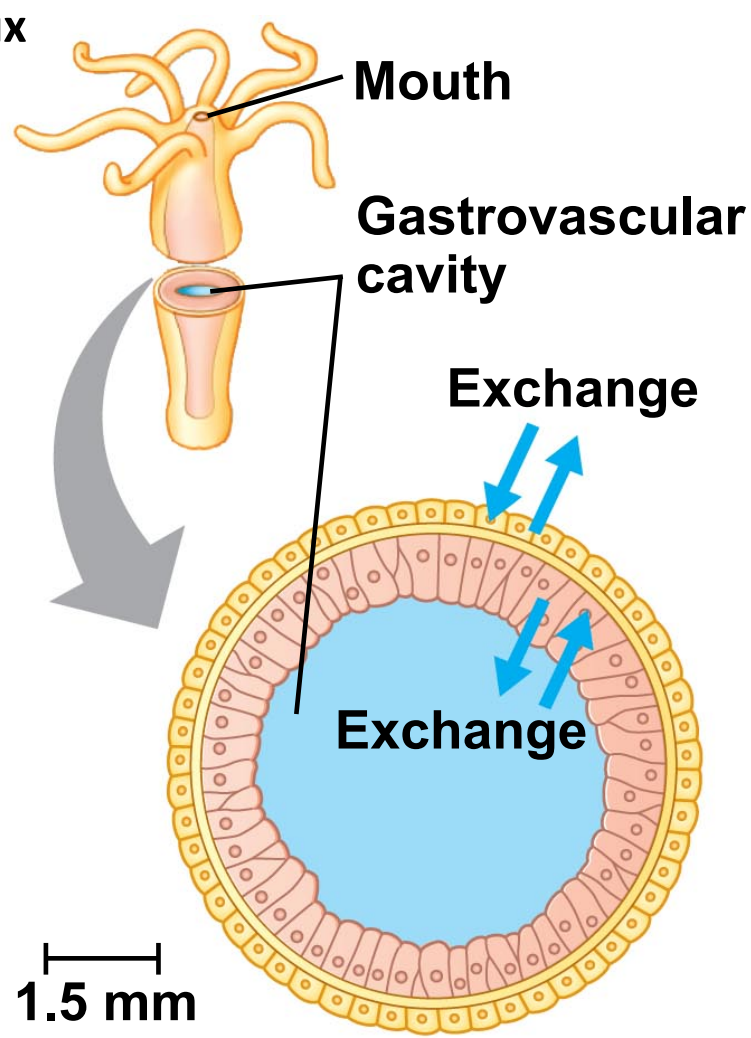

(b) Two layers of cells

Système digestif: problèmes principaux

- Problématique:
  - Besoin de 20 acides aminés dans le régime alimentaire!
  - Synthèse d'environ 10 acides aminés depuis les aliments?
  - Comment obtenir les acides aminés essentiels?
  - Conséquence d'un régime alimentaire carencé en acides aminés essentiels?

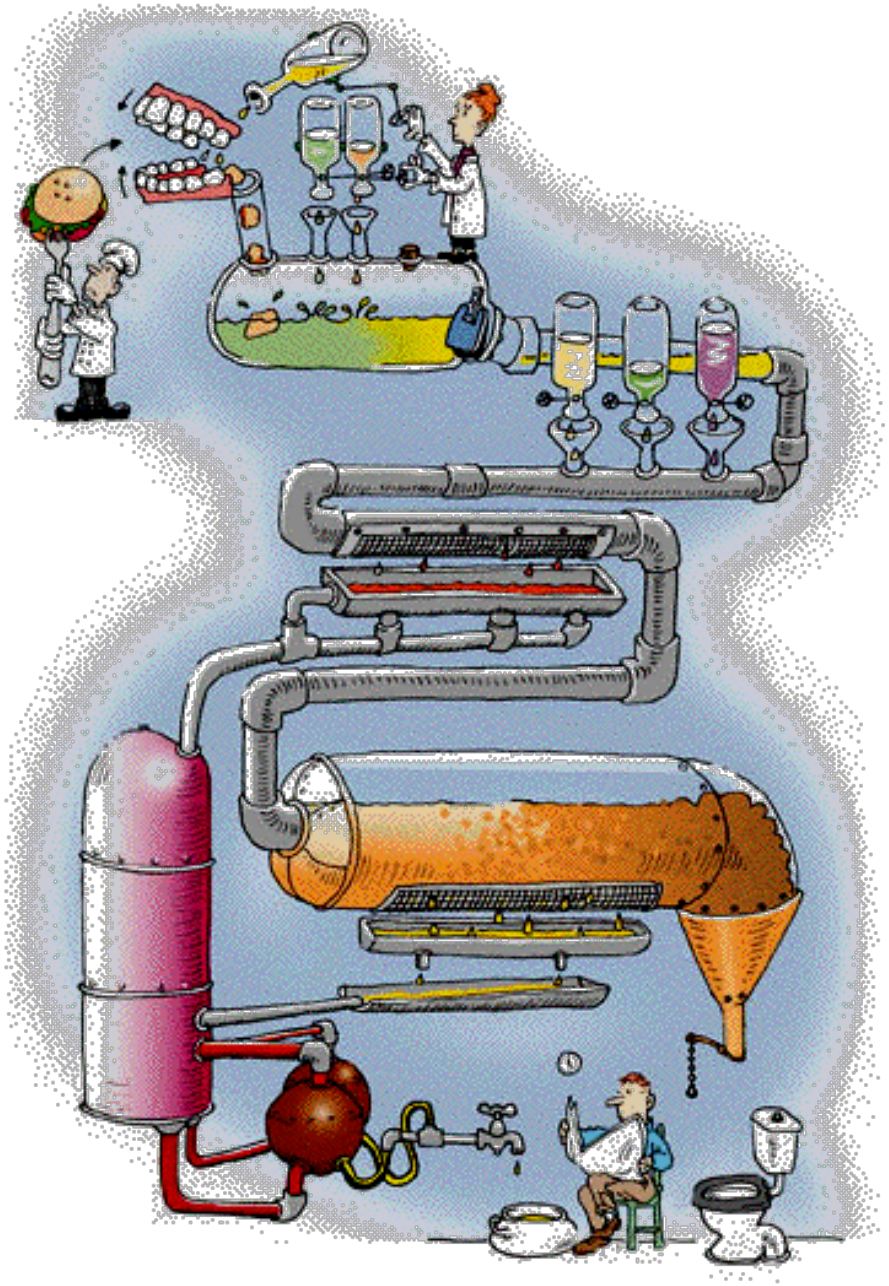

Système digestif Structure générale

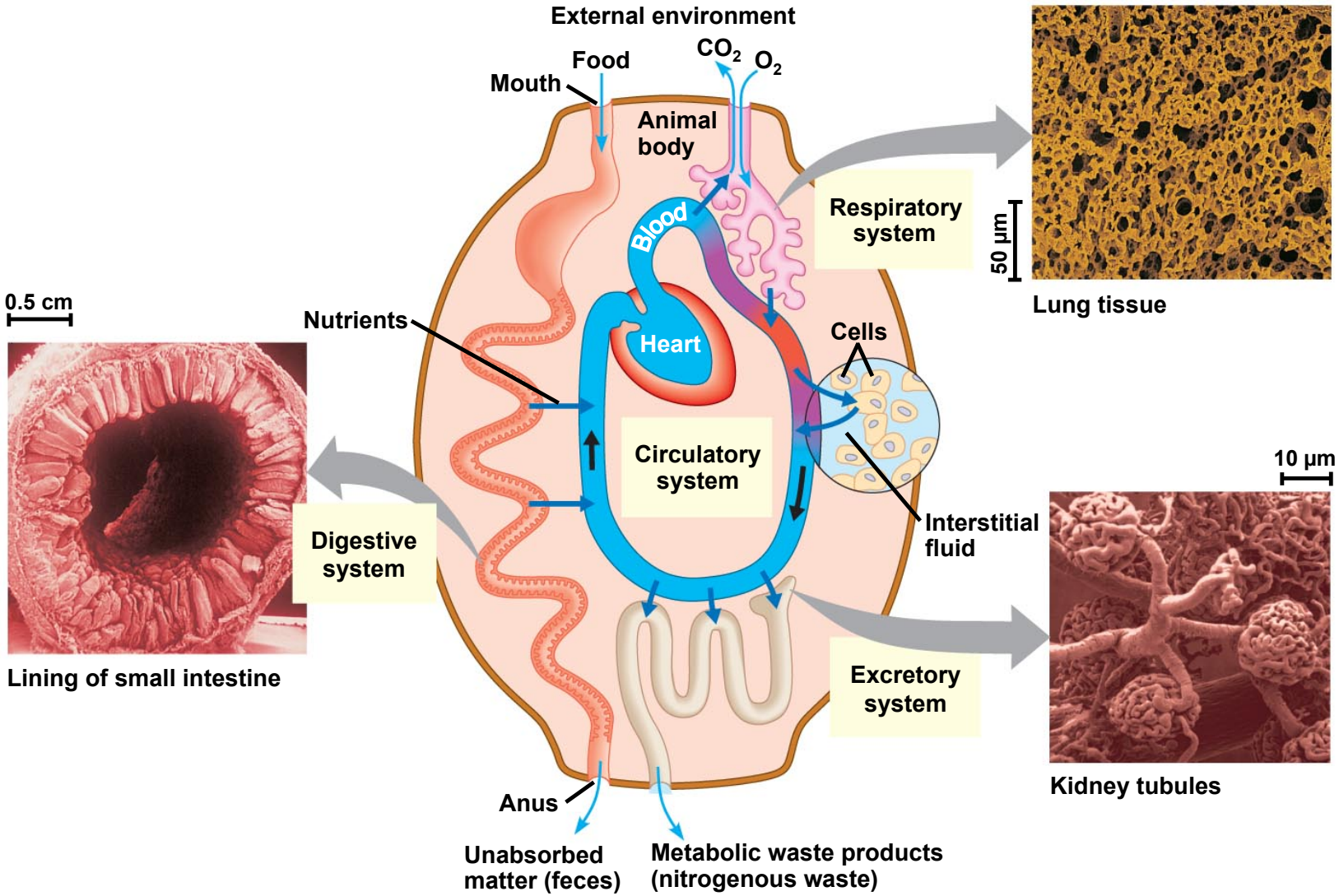

Système digestif Anatomie des voies digestives

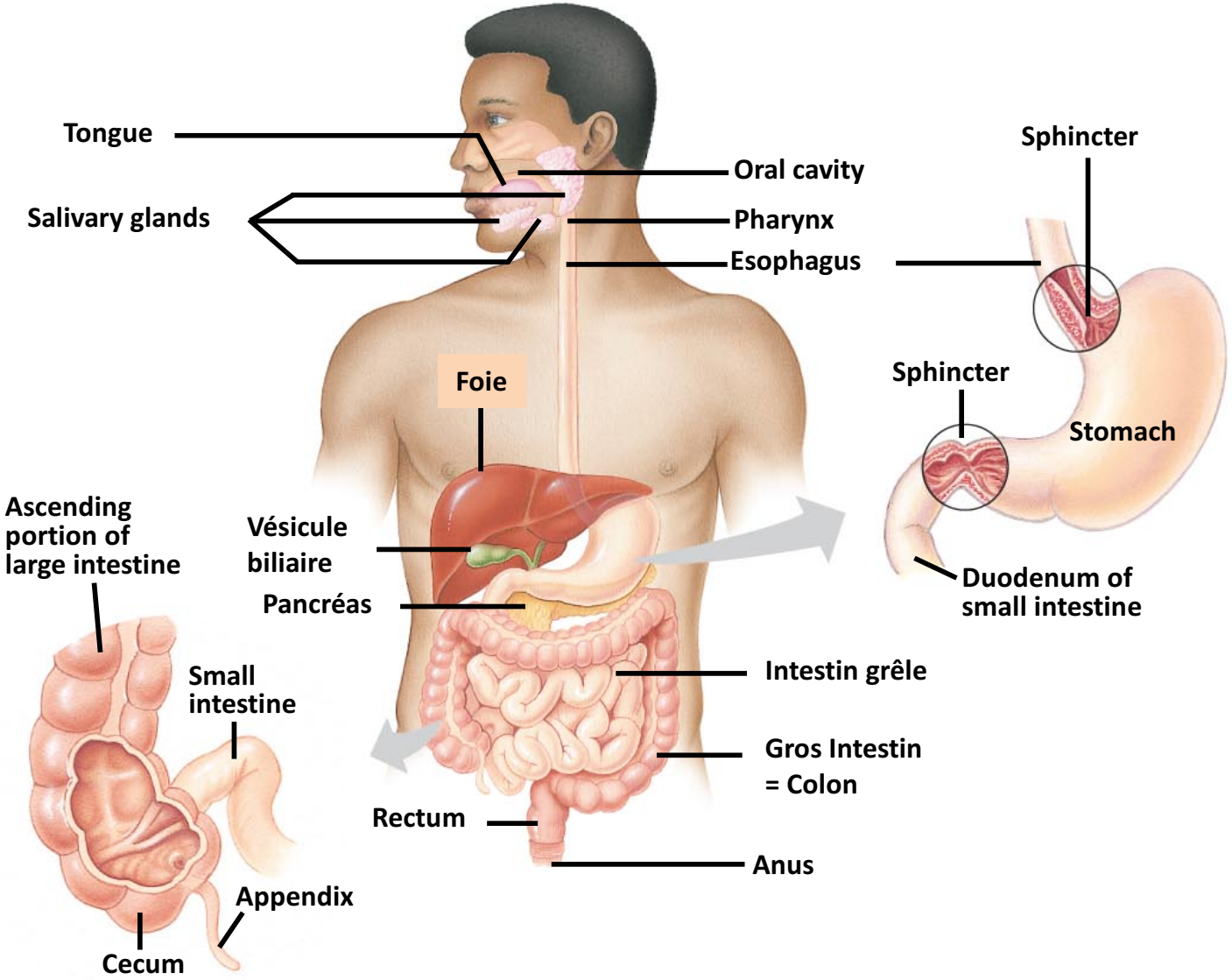

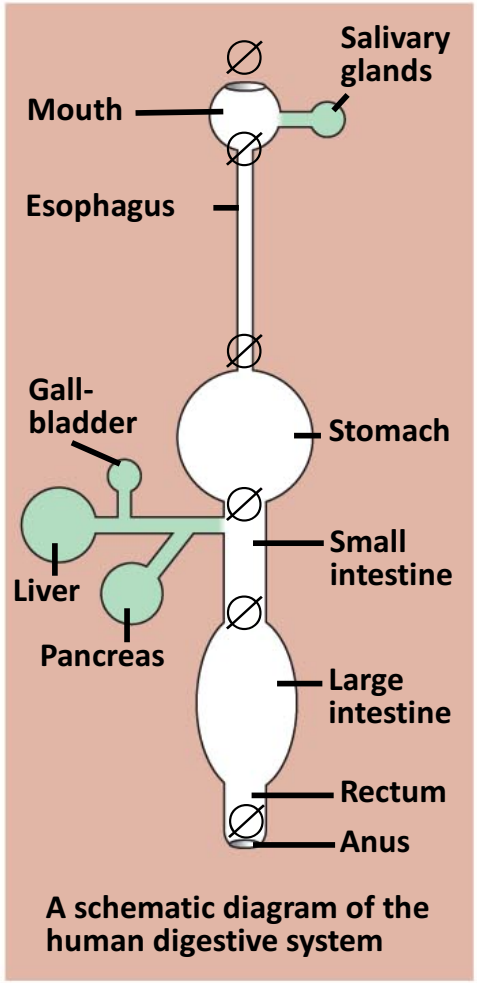

A schematic diagram of the human digestive system

Système digestif Anatomie du tube digestif: section de la paroi

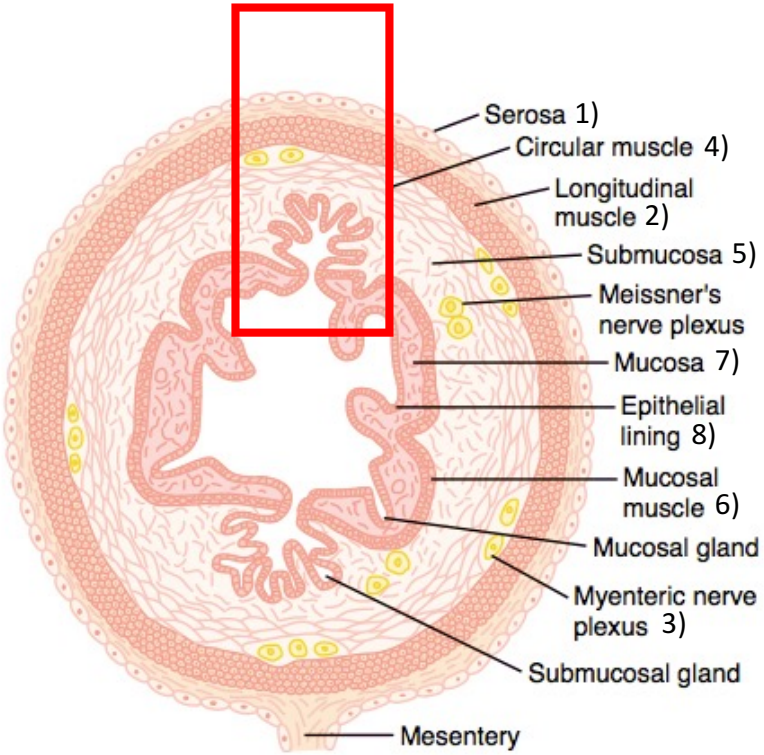

Figure 62–2

Typical cross section of the gut.

Le tube digestif

1) Séreuse
2) Muscle longitudinal
3) Plexus myentérique
4) Musculature circulaire
5) Sous-muqueuse
6) Muscle muqueux
7) Muqueuse
8) Epithélium

Externe

Lumen

Guyton et Hall Medical Physiology 340

Système digestif Anatomie du tube digestif: musculature lisse

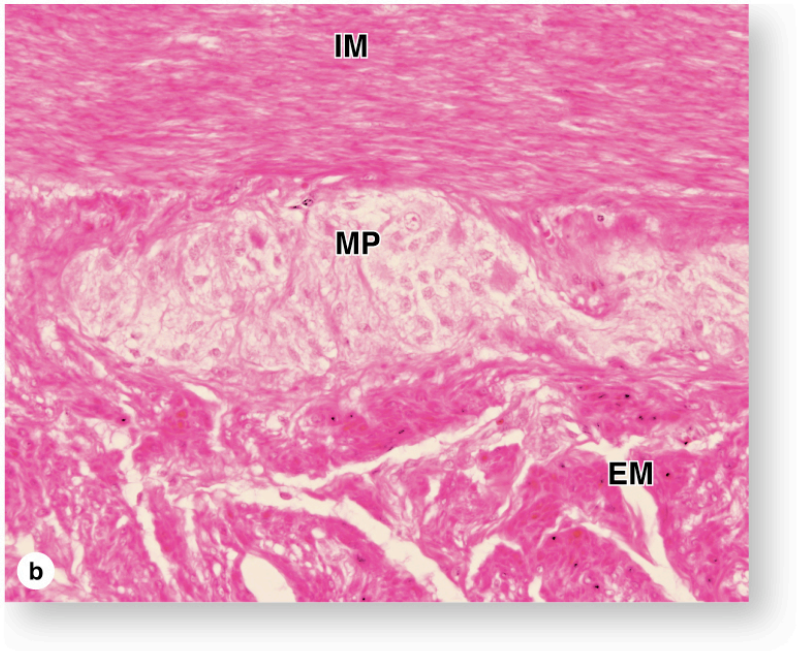

La musculature lisse gastrointestinale fonctionne comme un syncytium

1) Fibres de 200 à 500 µm de long
2) Connectés électriquement *(gap junctions)*
3) Le potentiel d'action PA voyage dans toutes les directions
4) Distance du PA selon l'excitabilité
5) Du mm au mètre

Small intestine muscularis and myenteric plexus.
Transverse sections of the small intestinal wall show the orientation of the *internal* (**IM**) and *external* (**EM**) *smooth muscle layers*. The inner layer is predominantly circular while the outer layer is longitudinal. (b): Pale—staining neurons and other cells in one *myenteric plexus* (**MP**) are seen between the two muscle layers. X100. H&E. Along the entire digestive tract autonomic neurons from the numerous myenteric ganglia and smaller submucosal ganglia innervate the wall and comprise the enteric nervous system, which is of key importance for gut function and involved in many digestive problems. Local activity of these neurons is controlled by sensory neurons and effector neurons supplying the musculature, both of which are intrinsic to the enteric nervous system. Extrinsic innervation in this system includes ***parasympathetic cholinergic nerve*** fibers that stimulate the activity of smooth muscle and *sympathetic adrenergic nerve* fibers that depress muscle activity.

Système digestif Anatomie du tube digestif: cellules intertitielles de Cajal

- are of mesenchymal origin
- turn over every 9 months (apoptosis, transdifferentiation / trophic factors)
- form a communication network
- are interposed between nerve and smooth muscle cells
- can cause motor disorders

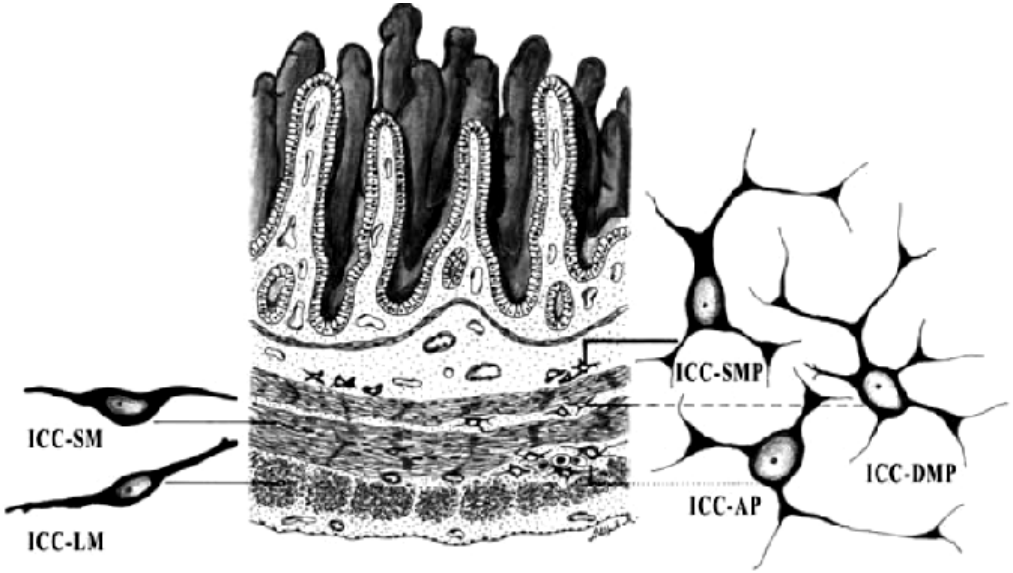

Sanders

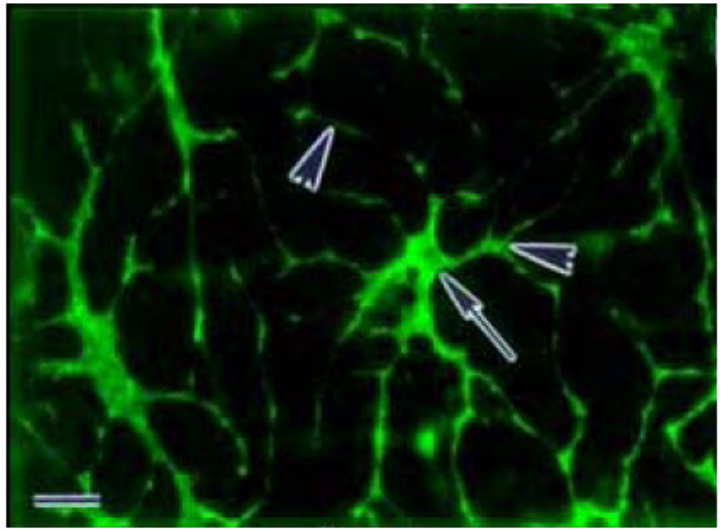

Distribution of interstitial cells of Cajal (ICC) in the intestinal wall. ICC-AP- cells are located between the circular and longitudinal smooth muscle layer, and around the ganglial cells of the myenteric plexus; ICC-DMP-cells are present between the thin inner and thick outer sublayer of the circular muscle layer of the small intestine; ICC-SMP-cells are located on the submucous margin of the circular muscle layer; ICC-CM-cells are located within the circular muscle layer; and ICC-LM-cells are found within the longitudinal muscle layer.

Deep Muscular Plexus (DMP)

Auerbach's myenteric plexus (AP)

Sub Mucous Plexus (SMP)

FACTA UNIVERSITATIS
Series: **Medicine and Biology** Vol.12, No 1, 2005, pp. 1 - 5

INTERSTITIAL CELLS OF CAJAL PACEMAKERS OF THE INTESTINAL MUSCULATURE

Goran Radenković[1], Ivan Nikolić[1], Vera Todorović[2]

Système digestif Anatomie du tube digestif: oesophage

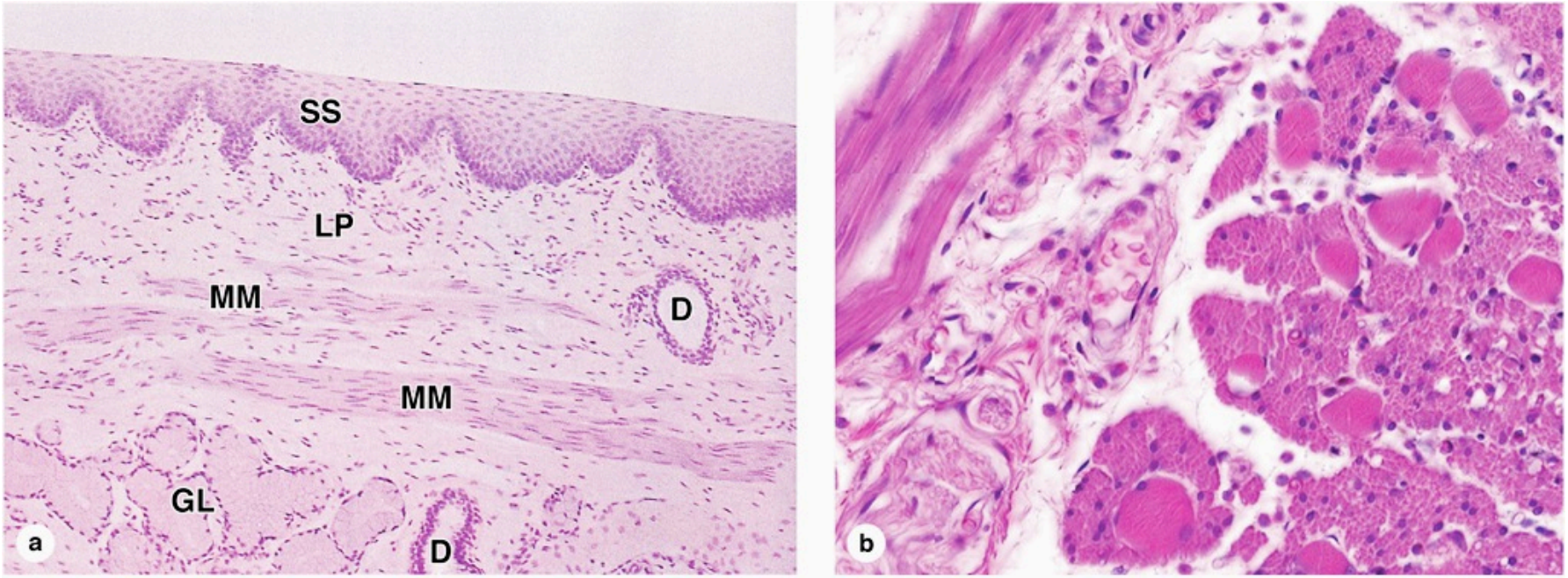

(a): Longitudinal section of esophagus shows mucosa consisting of **nonkeratinized stratified squamous epithelium** (**SS**), **lamina propria** (**LP**), and **smooth muscles of the muscularis mucosae** (**MM**). Beneath the mucosa is the submucosa containing **esophageal mucous glands** (**GL**) which empty via **ducts** (**D**) onto the luminal surface. X40. H&E. (b): Transverse section showing the muscularis halfway along the esophagus reveals a combination of **skeletal muscle** (right) and **smooth muscle fibers** (left) in the outer layer, which are cut both longitudinally and transversely here. This transition from muscles under voluntary control to the type controlled autonomically is important in the swallowing mechanism. X200. H&E.

Système digestif Anatomie du tube digestif: sphincter de l'oesophage

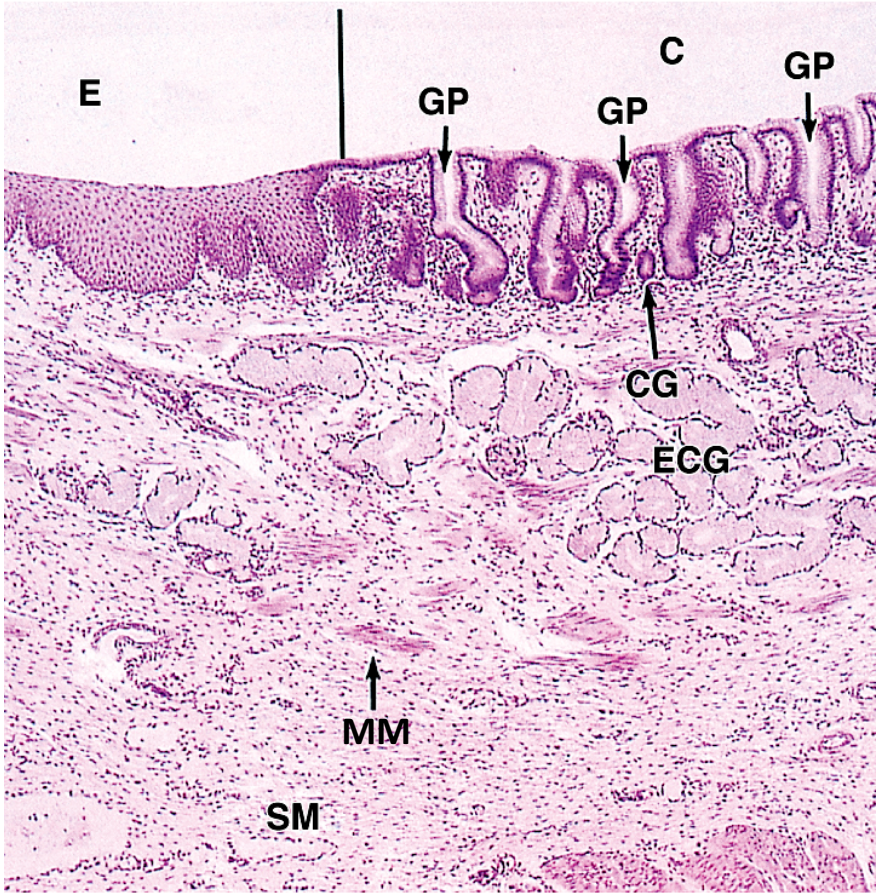

Fonction du sphincter oesophagien inférieur
- pression intraluminale (20-30 mmHg)
- relaxation réceptive

Esophagogastric junction. At the junction of the esophagus (**E**) and the cardiac region of the stomach (**C**) there is an abrupt change in the mucosa from stratified squamous epithelium to simple columnar epithelium invaginating as gastric pits (**GP**). The mucosa contains many mucus—secreting esophageal cardiac glands (**ECG**), whose function is supplemented by mucous cardiac glands (**CG**) opening into the superficial gastric pits. Strands of muscularis mucosae (**MM**) separate the mucosa and submucosa (SM). X60. H&E.

gastric pits = cryptes gastriques

Système digestif Anatomie du tube digestif: estomac

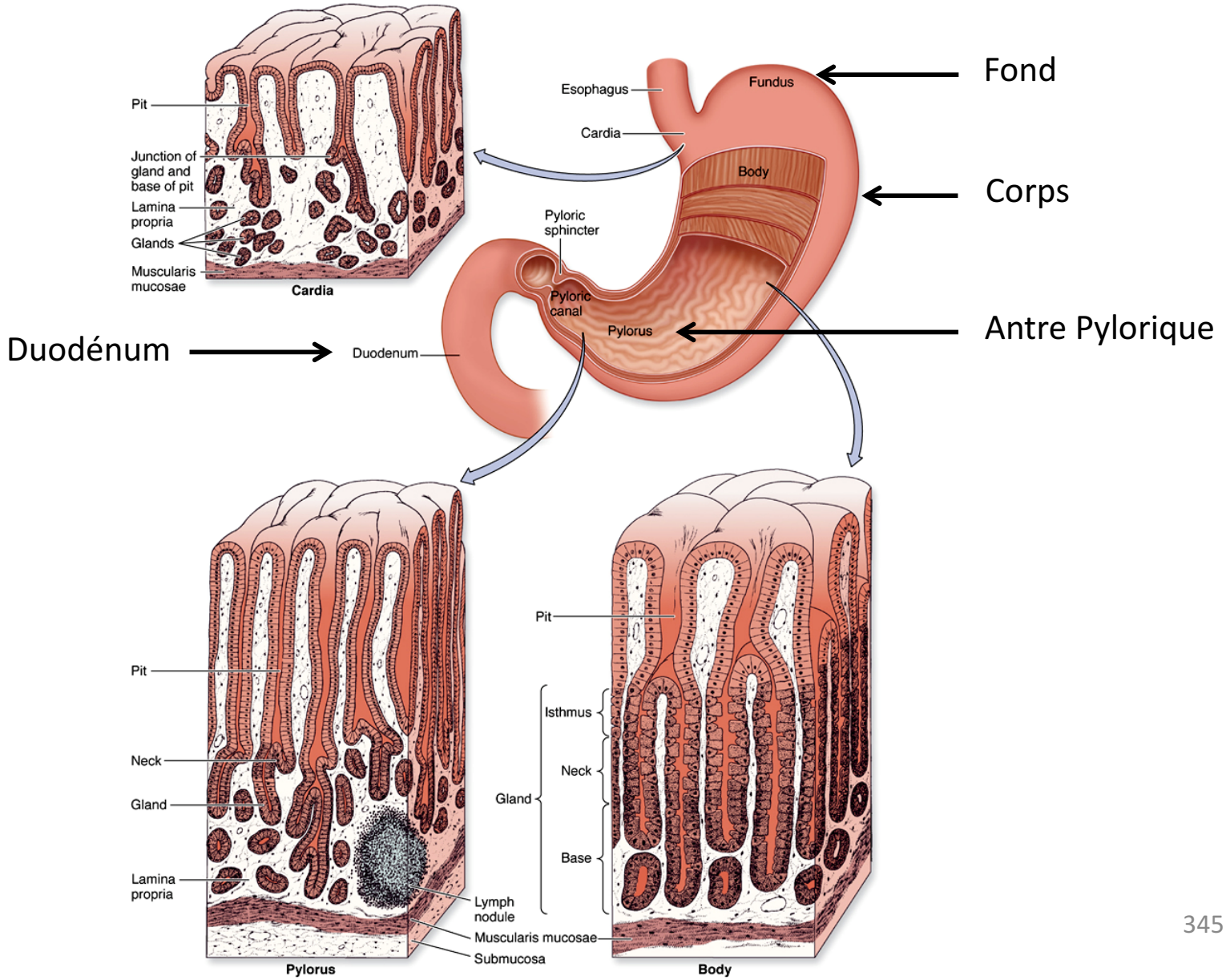

Système digestif Anatomie du tube digestif: structures de l'estomac

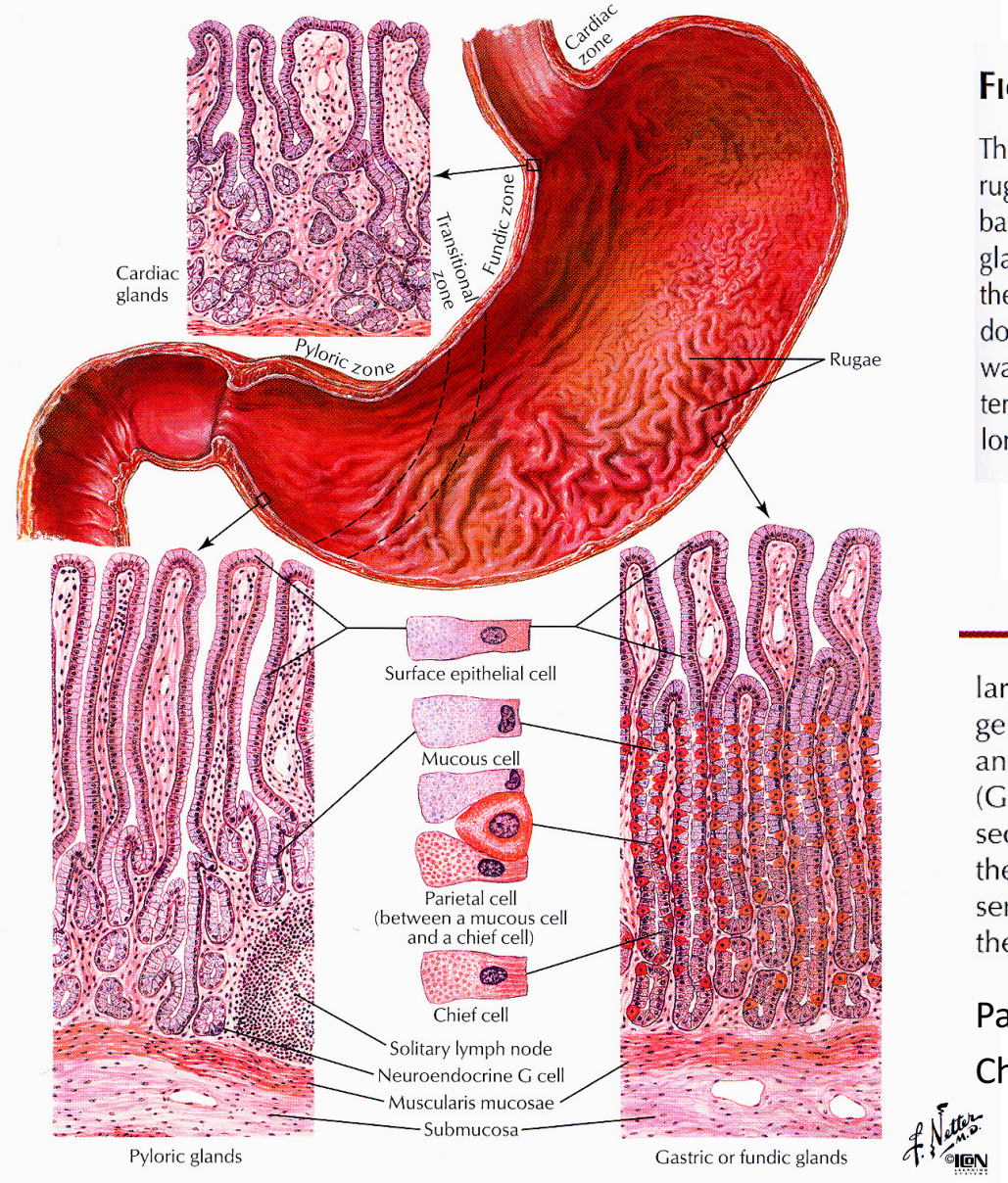

FIGURE 7.9 STRUCTURE OF THE STOMACH

The surface of the stomach is thrown into numerous folds called rugae. The epithelium forms gastric pits with gastric glands at their base; these pits greatly increase the surface area for secretion. The glands differ in structure and cellular composition depending on their location. The cardiac glands are short and branched; the predominant cell type is the mucous cell. The mucous cells produce a watery (low-mucin) secretion that helps liquefy the gastric contents. The gastric or fundic glands are most numerous and form long, straight glands. In addition to mucous cells, they contain large numbers of parietal (HCl-secreting) cells and chief, or zymogen (pepsinogen-secreting), cells. The pyloric glands are branched and are composed mostly of mucous cells. Neuroendocrine cells (G cells) are found in the pyloric glands and are the cells that secrete gastrin. Surface epithelial cells are found in all regions of the stomach. They produce a thick (high-mucin) mucus, which serves to protect the surface cells of the stomach from abrasion by the ingested food.

Parietal cells = HCl cells

Chief cells = pepsinogen cells

Epithelial cells = mucin cells

G cells = gastrin cells

Système digestif Anatomie du tube digestif: structures de l'intestin

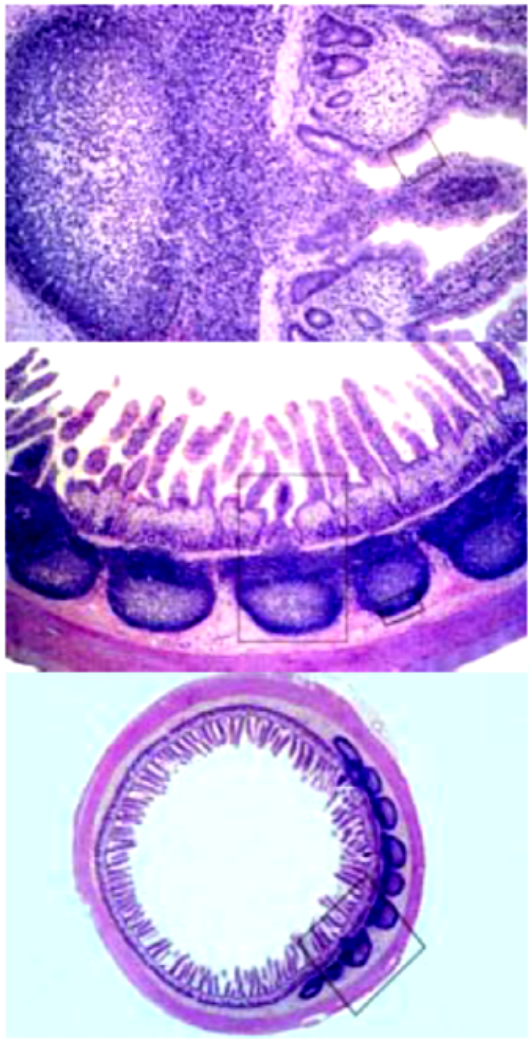

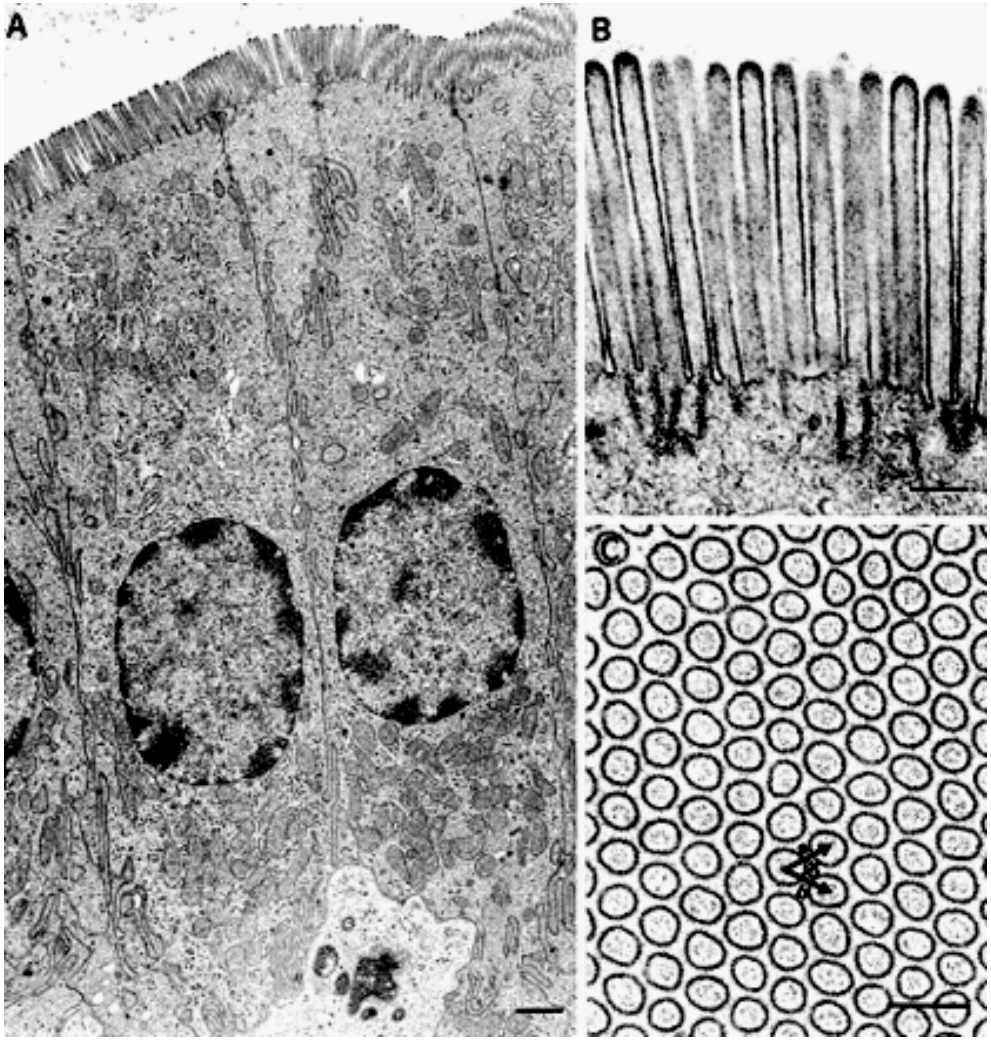

Système digestif Anatomie du tube digestif: structures de l'intestin

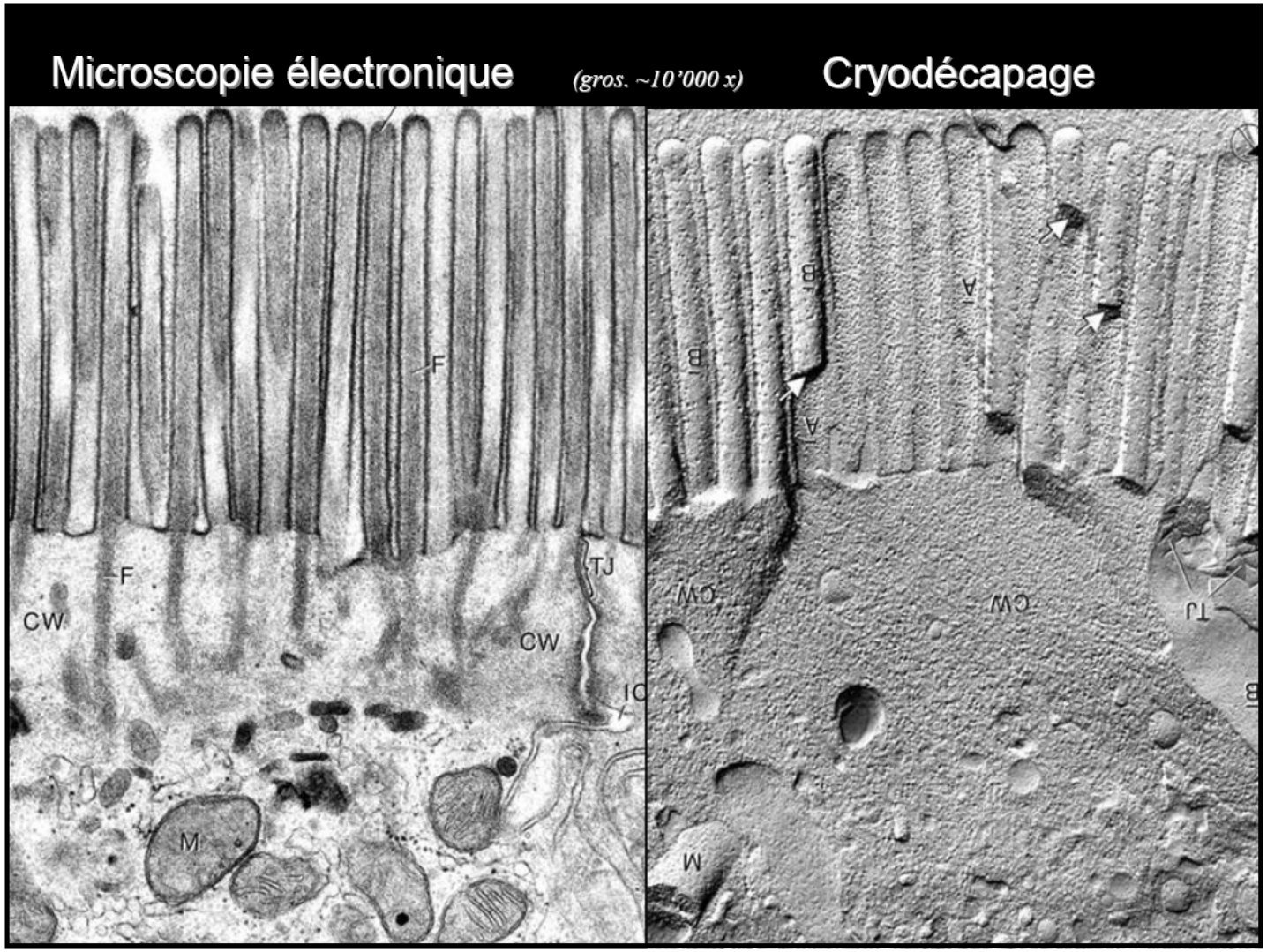

Système digestif Image radiologique du cadre colique

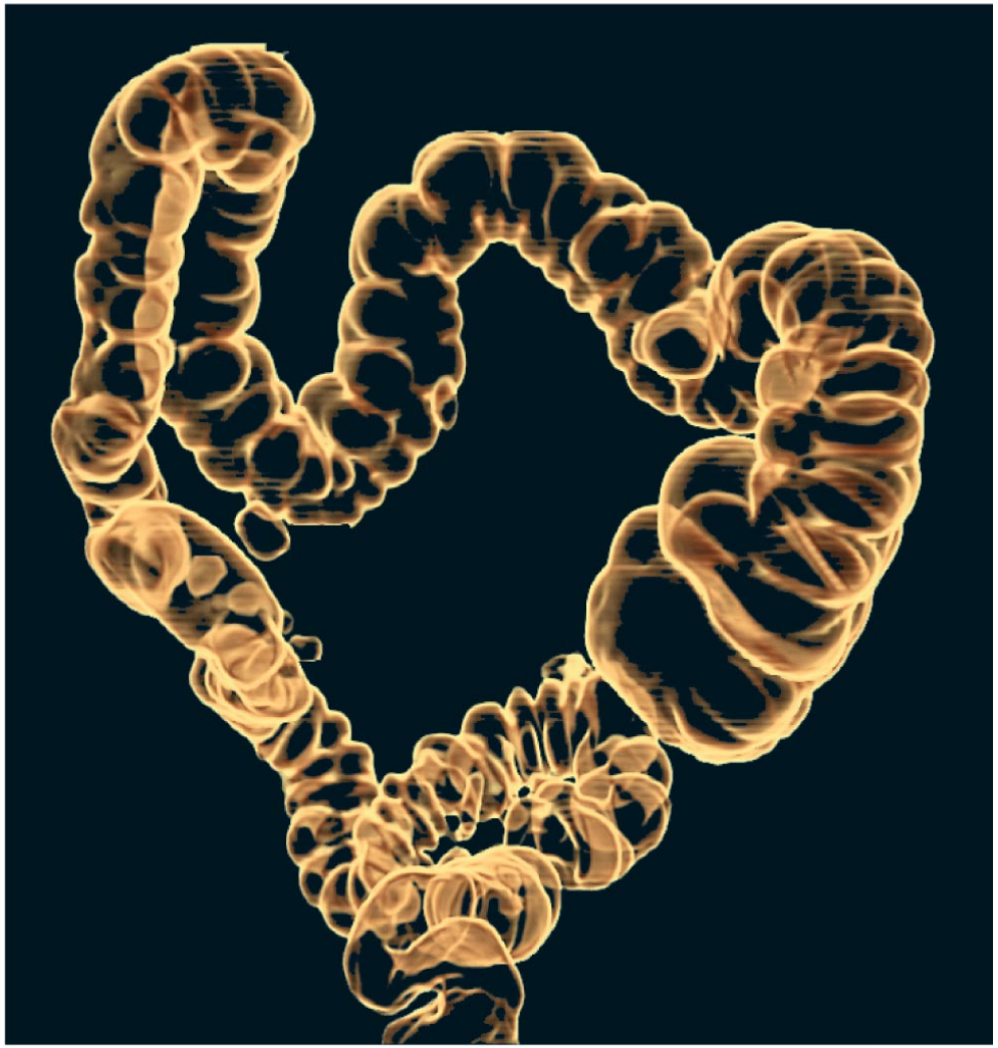

Système digestif Anatomie du tube digestif: structure du foie

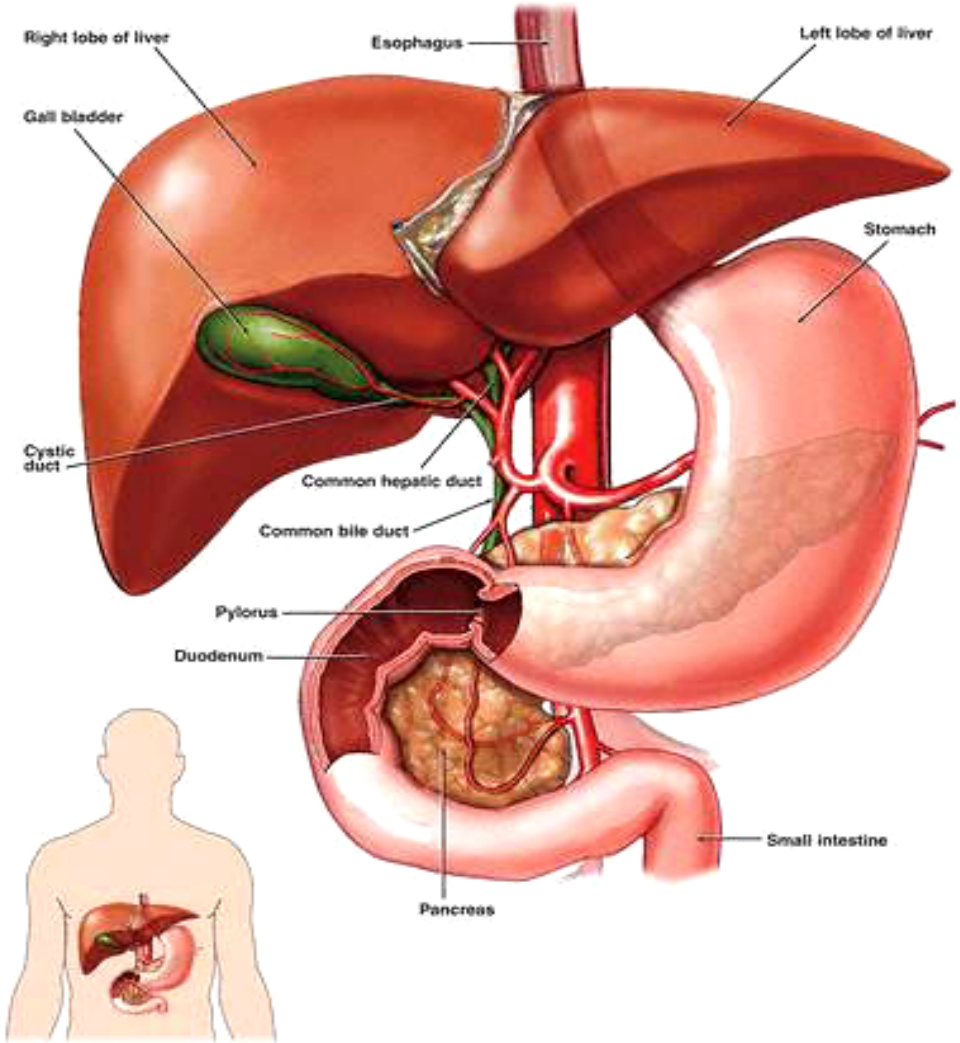

Caractéristiques

Le plus grand organe
Masse: 1200-1500 g 2-5% MCT
Position stratégique dans la circulation
L'organe le plus régénératif du corps

Rôles

Traitement aliments, stockage, synthèse
Essentiel à l'homéostasie métabolique
Usine chimique
Système excrétoire
Glande exocrine (bile)
Glande endocrine (Pro-Hormone)
Détoxification
Transformation des xénobiotiques

Système digestif Anatomie du tube digestif: structure du foie

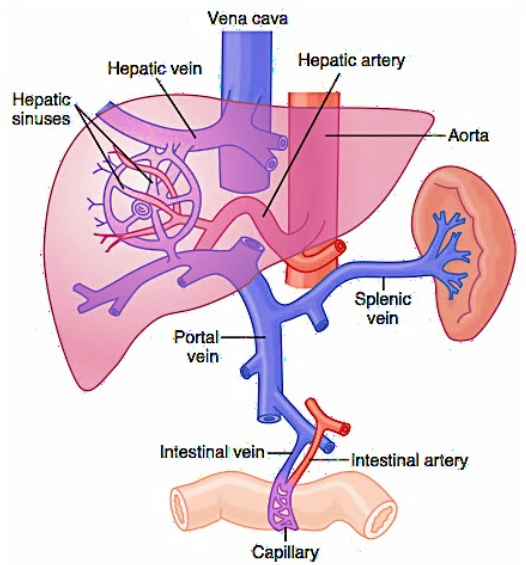

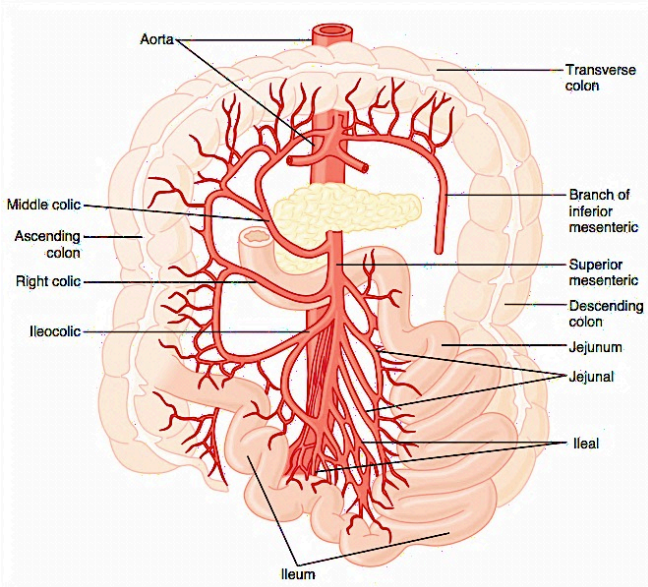

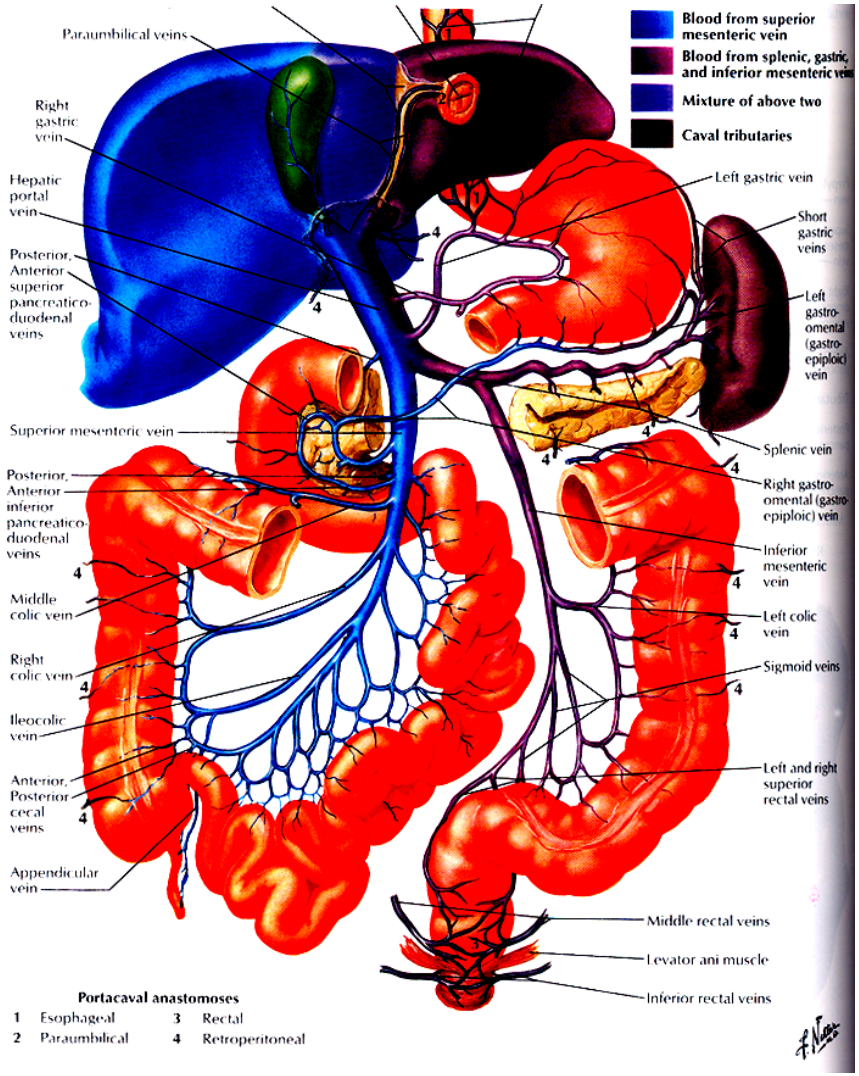

Système digestif Anatomie du tube digestif: structure du foie les canaux

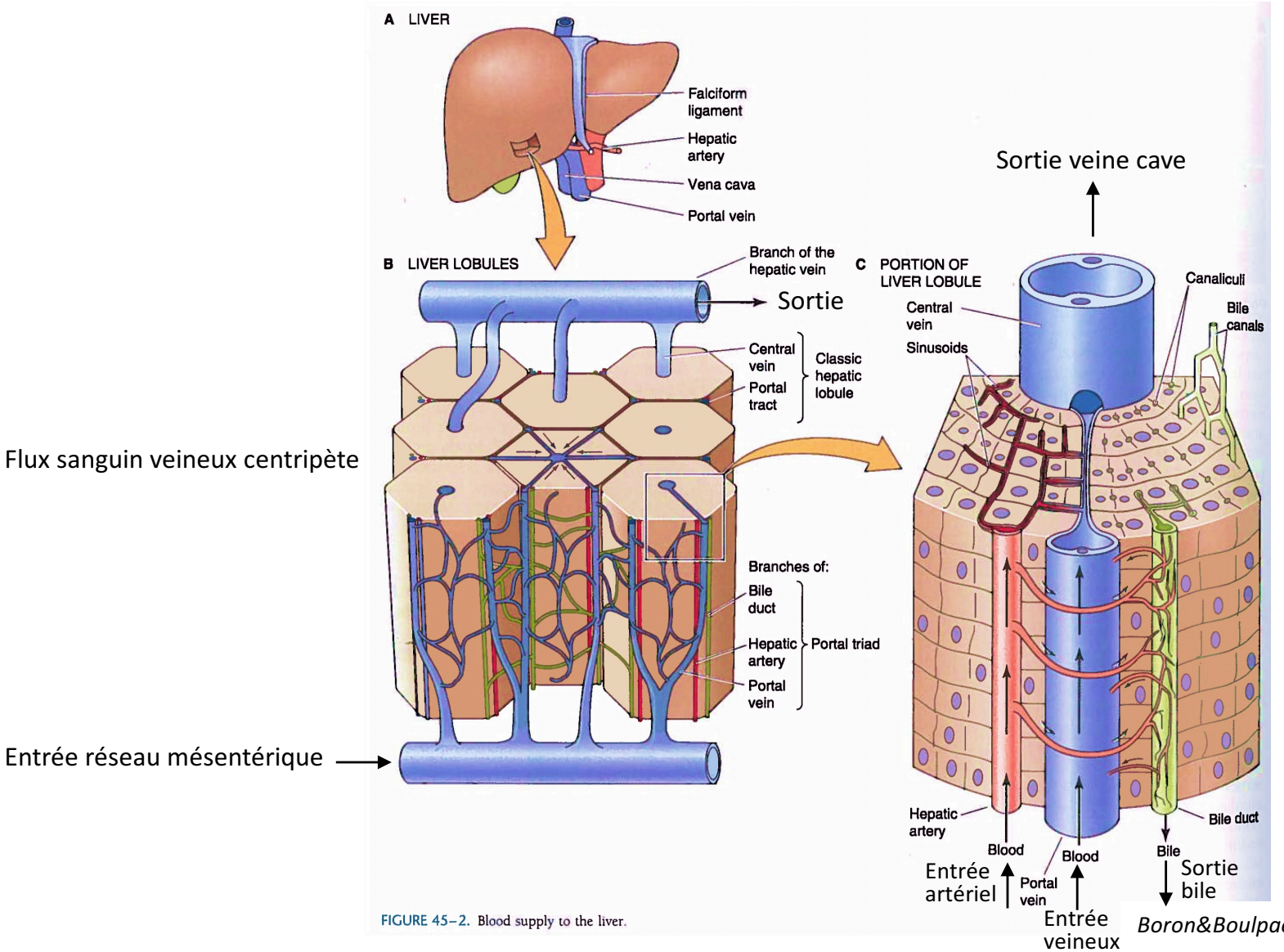

FIGURE 45–2. Blood supply to the liver.

Boron&Boulpaep Medical Physiology 352

Système digestif Anatomie du tube digestif: structure du foie les canaux

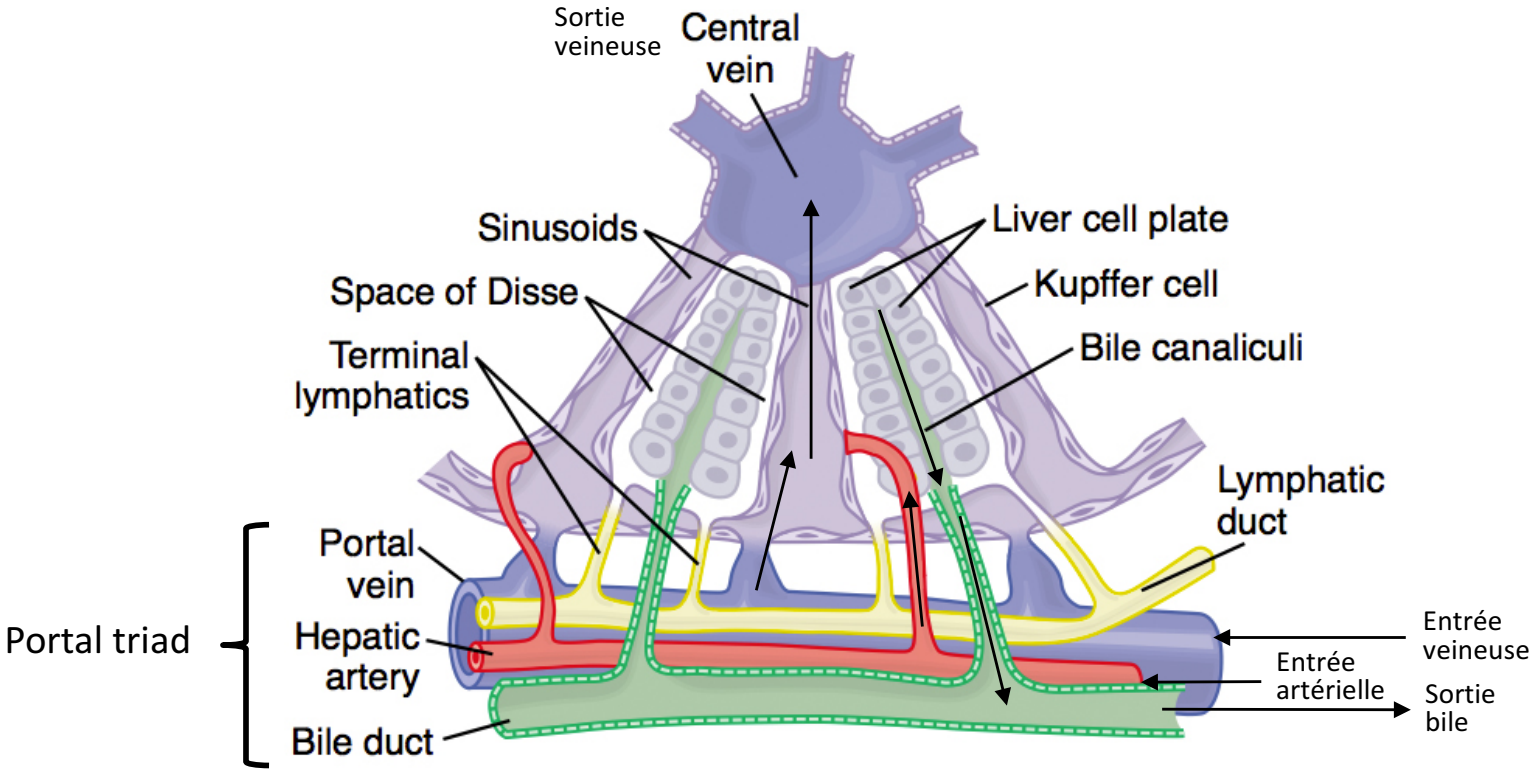

Figure 70–1

Basic structure of a liver lobule, showing the liver cellular plates, the blood vessels, the bile-collecting system, and the lymph flow system composed of the spaces of Disse and the interlobular lymphatics. (Modified from Guyton AC, Taylor AE, Granger HJ: Circulatory Physiology. Vol 2: Dynamics and Control of the Body Fluids. Philadelphia: WB Saunders, 1975.)

Guyton et Hall Medical Physiology 353

Système digestif Anatomie du tube digestif: structure du foie le lobule

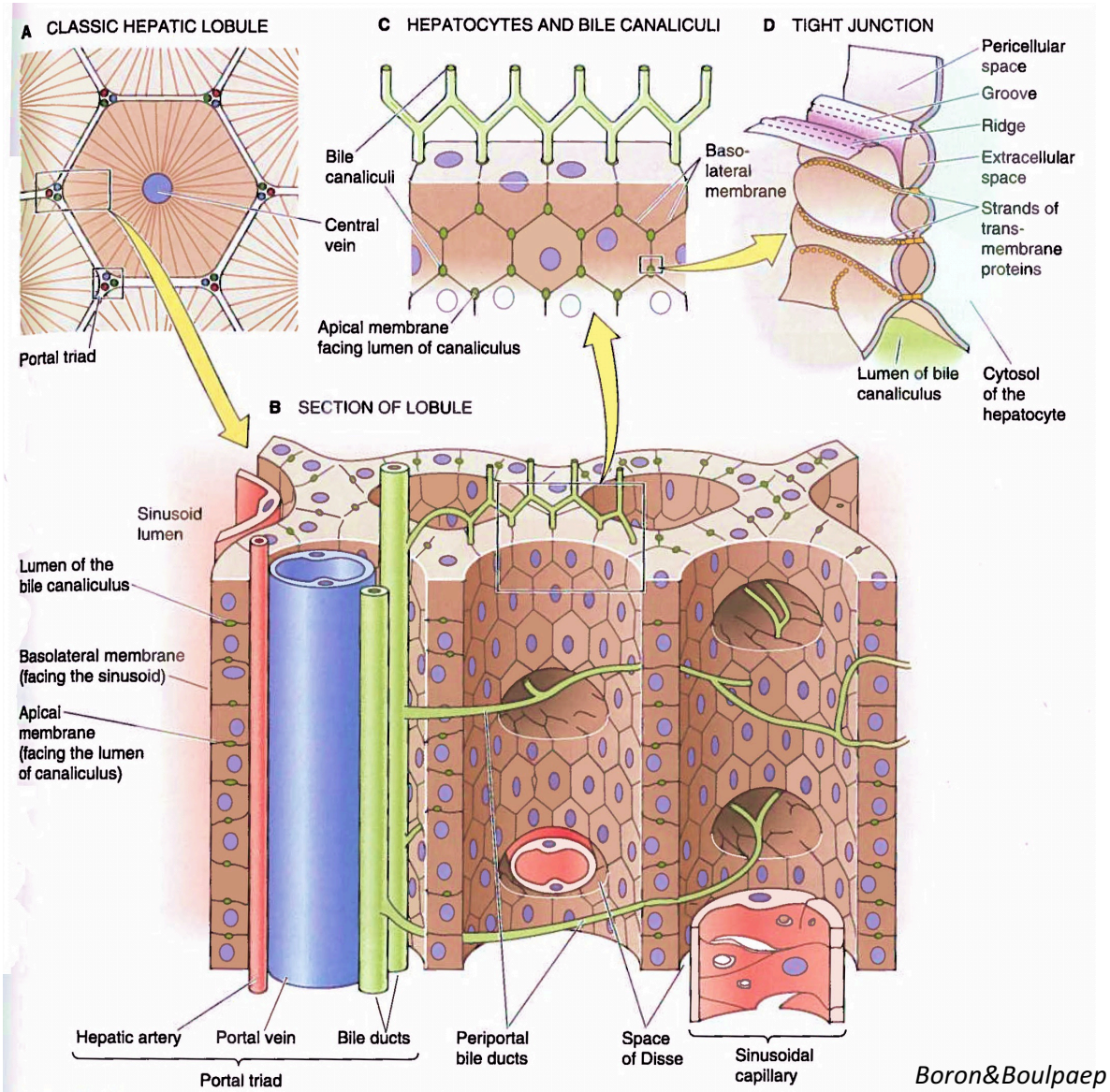

FIGURE 45-1. Hepatocytes, sinusoids, and the intrahepatic bile system.

Boron&Boulpaep Medical Physiology 354

Système digestif Anatomie du tube digestif: structure du foie le lobule

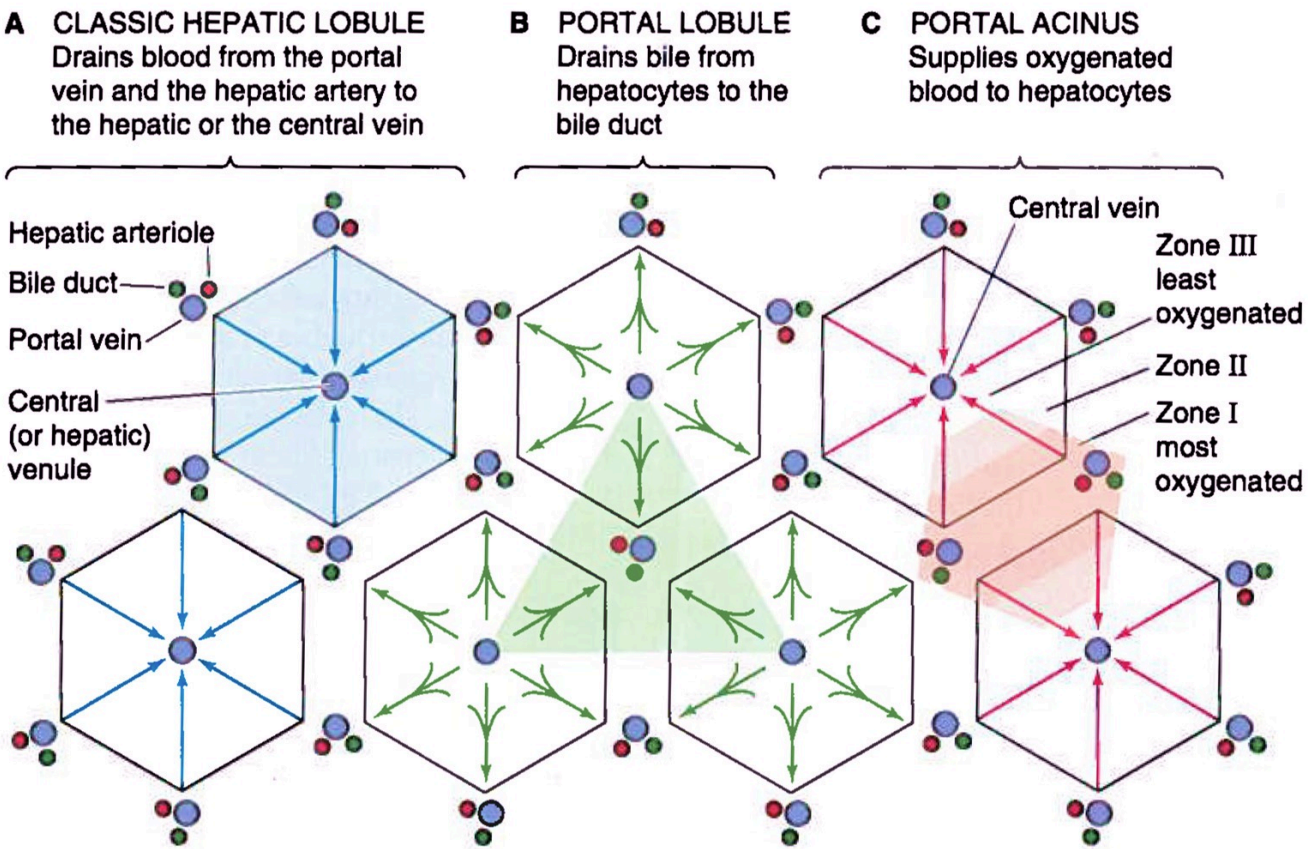

FIGURE 45–3. Zones in the acinus. *A*, The classic lobule includes all hepatocytes drained by a single central vein. At each corner of the hexagon are triads composed of branches of the hepatic artery, portal vein and bile duct. *B*, The portal lobule includes all hepatocytes drained by a bile ductule. *C*, This organization emphasizes the arterial blood supply to the hepatocytes and thus the oxygenation gradient between a branch of the hepatic artery and branches of the hepatic vein (i.e., central vein). The periportal hepatocytes of zone I immediately surround the portal tract and thus have the highest PO_2 and the most nutrients. They specialize in oxidative metabolism and certain other functions. The pericentral hepatocytes of zone III surround the central vein and have the lowest PO_2. The zone-III hepatocytes specialize in biotransformations and drug detoxification. Zone II is an intermediate zone between zones I and III.

Boron&Boulpaep Medical Physiology 355

Système digestif Anatomie du tube digestif: structure du foie les voies biliaires

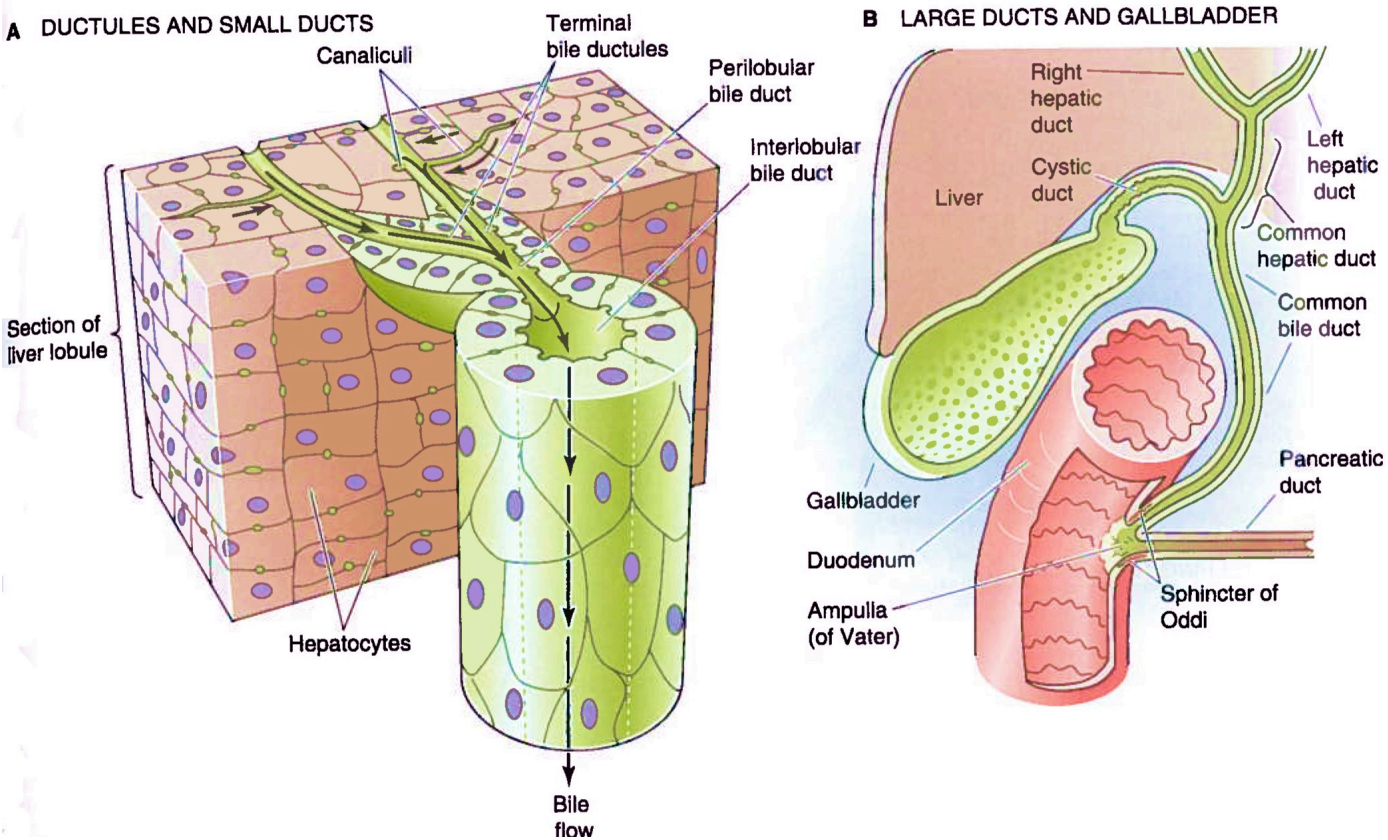

A The **bile canaliculi**, which are **formed by the apical membranes of adjacent hepatocytes**, eventually merge with **terminal bile ductules** (canals of Hering). The ductules eventually merge into **perilobular ducts**, and then **interlobular ducts**.

B The interlobular ducts merge into **septal ducts**, **lobar ducts**, and eventually the **right and left hepatic ducts**, which combine as the common hepatic duct. The confluence of the **common hepatic** and the **cystic ducts** gives rise to the **common bile duct.** The common bile duct may merge with the pancreatic duct and form the **ampulla of Vater** before entering the **duodenum**, as shown in the figure, or have a completely independent lumen. In either case, there is a **common sphincter-the sphincter of Oddi-that simultaneously regulates flow out of the common bile duct and the pancreatic duct.**

Système digestif Anatomie du tube digestif: structure du foie

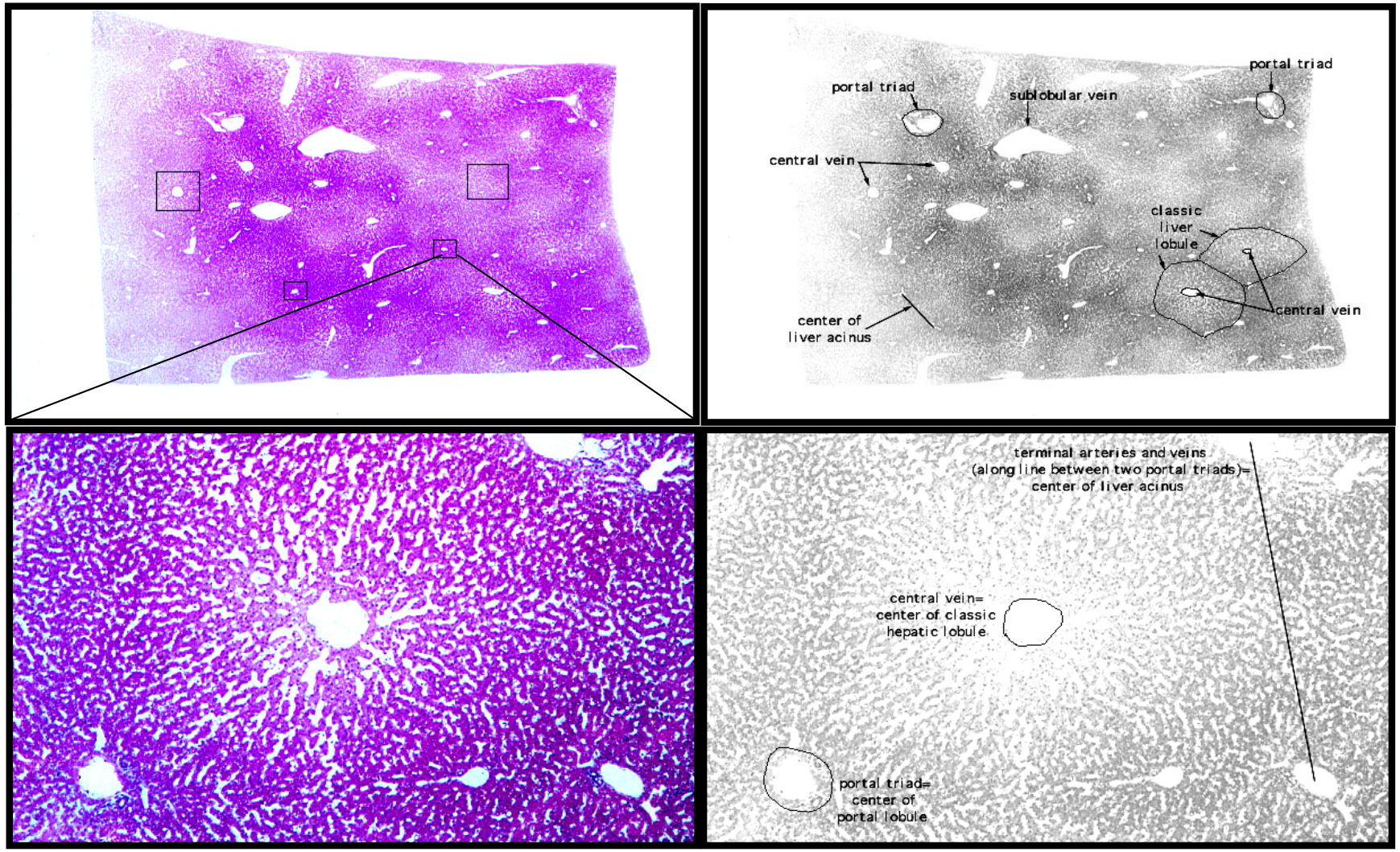

Système digestif Anatomie du tube digestif: structure du foie

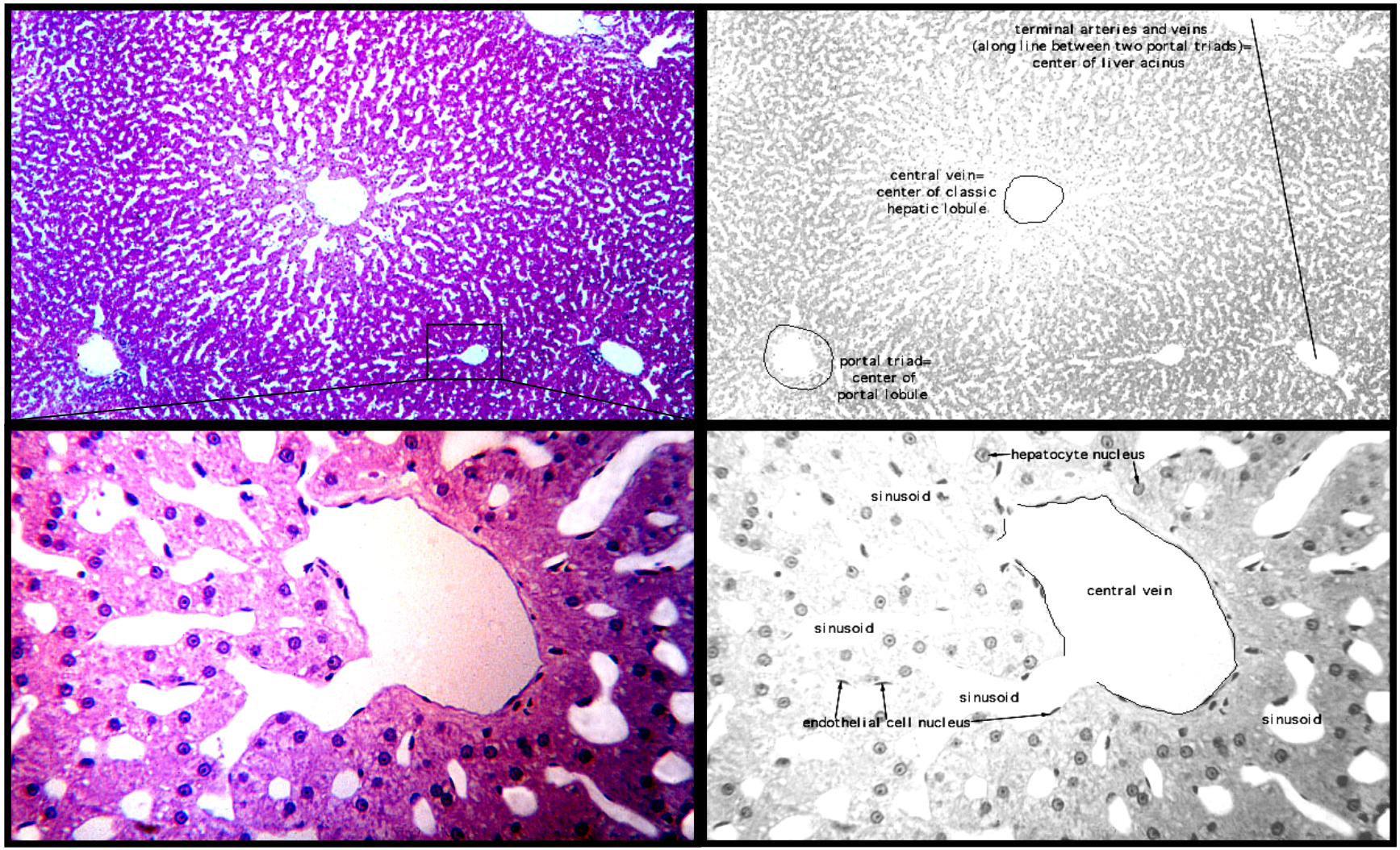

Système digestif Anatomie du tube digestif: structure du foie

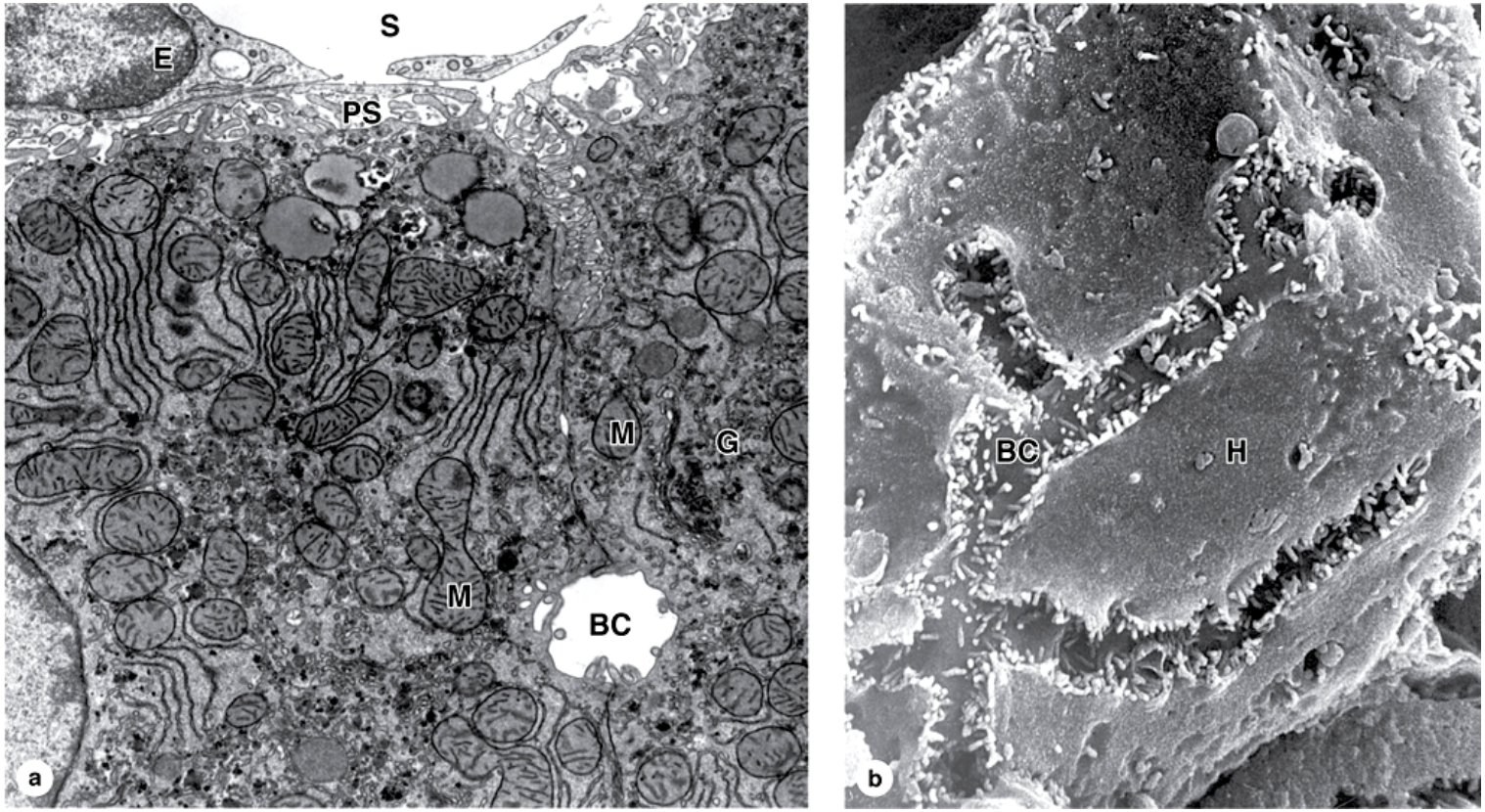

(a): TEM of hepatocytes show small bile canaliculi (**BC**) between two cells, with junctional complexes binding the cells firmly and tightly at these sites. The bile canaliculus is the site of exocrine secretion by hepatocytes. The two adjoining hepatocytes extend short microvilli and secrete bile components into this space. The hepatocytes have many mitochondria (**M**), small electron—dense glycogen granules, and Golgi complexes (**G**) and extend more numerous microvilli into the perisinusoidal space (**PS**), which is the site where hepatocytes remove and add components in plasma. The endothelial cell (**E**) lining the sinusoid (**S**) is also seen. X9500. (b): SEM of hepatocytes (**H**) broken apart from one another reveals the length of a bile canaliculus (**BC**) along the cell's surface. Such canaliculi run between the cells of the hepatocyte plates in the hepatic lobules and carry bile toward the portal areas where the canaliculi join cuboidal bile ductules.

Système digestif Anatomie du tube digestif: structure du foie

BC = bile canaliculi
CF = Collagen fiber
DS = Space of Disse
IC = Ito's cell
LD = lipid droplet
LS = Liver sinusoid
P = Process

Ito's cell = adult stem cell

Poorly differenciated mesenchymal cells

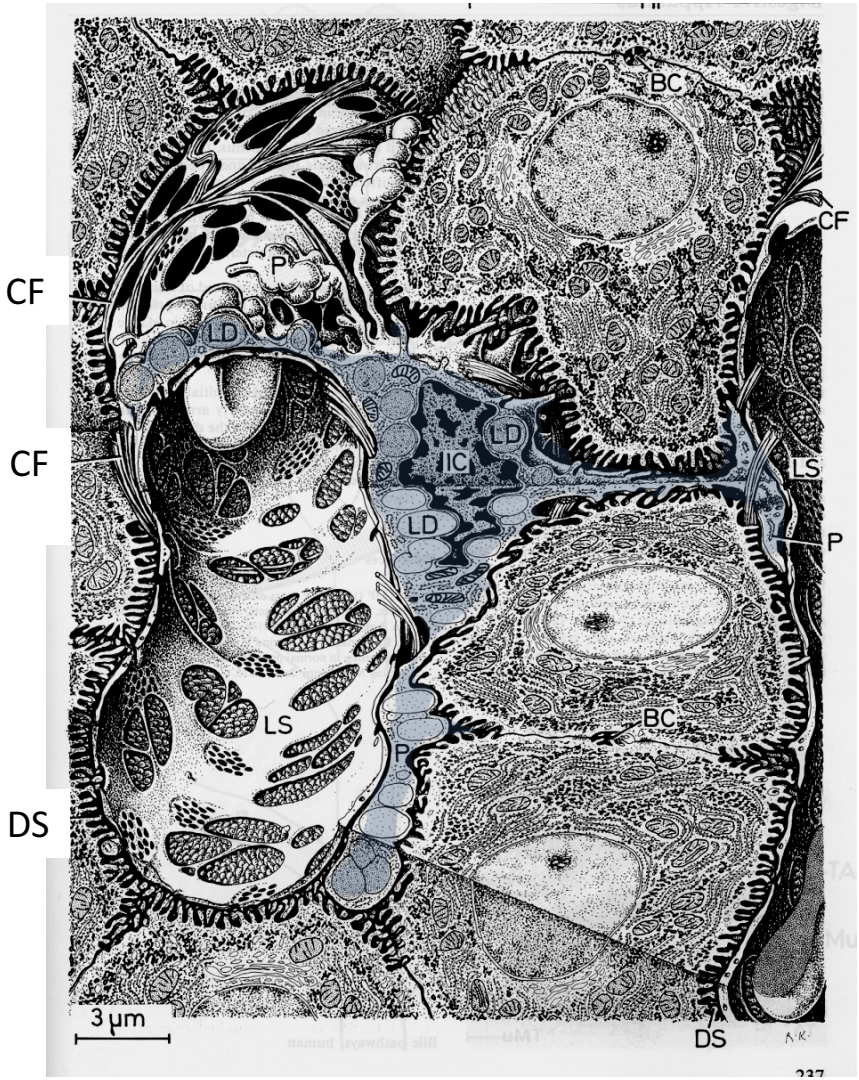

Système digestif Anatomie du tube digestif: structure du foie

H = hepatocyte
LS = Liver sinusoid
NF = nerve fiber
Mv = microvilosity
Ph = phagolysosome
DS = Space of Disse
KC = Kupfer's cell
Ho = Holes
F = filipodia

Kupfer's cell= macrophage